



# Paradental Cyst (Inflammatory Collateral Cyst): A True Clinicopathologic Entity

<sup>1</sup>Raveendranath Rajendran, <sup>2</sup>Hari Pillai, <sup>3</sup>Khalid Al Fouzan, <sup>4</sup>Anil Sukumaran

## ABSTRACT

Paradental cyst is an inflammatory odontogenic cyst arising in association with partially erupted third molars affected with pericoronitis. The common location is on the buccal aspect of the molar teeth. Radiographically, the characteristic presentation is a well-defined radiolucency superimposed on the roots. Histologically, cysts were lined with nonkeratinized epithelium. The various concepts underlining the origin/pathogenesis of this rare entity is discussed and critically appraised.

**Keywords:** Cyst, Paradental cyst, Pericoronitis.

**How to cite this article:** Rajendran R, Pillai H, Al Fouzan K, Sukumaran A. Paradental Cyst (Inflammatory Collateral Cyst): A True Clinicopathologic Entity. *Oral Maxillofac Pathol J* 2015;6(2): 621-624.

**Source of support:** Nil

**Conflict of interest:** None

## INTRODUCTION

A cyst of uncertain origin found primarily on the distal or facial aspect of a vital mandibular third molar, consisting of intensely inflamed connective tissue and epithelial lining.<sup>1</sup> The minor variations in the clinical appearance of the cyst make it feasible to consider two main groups separately: those associated with first and second permanent molars of the mandible and those associated with the third mandibular molar.<sup>2</sup> This is an inflammatory cyst which develops on the lateral surface of a tooth root. Some authors refer to this cyst as a paradental cyst<sup>3</sup> and is

of rare occurrence and must be radiographically differentiated from the lateral periodontal cyst (developmental origin). Vedtofte and Praetorius<sup>4</sup> suggested the use of the descriptive term 'Inflammatory paradental cyst', because of its inflammatory origin and also due to its location at the side of the tooth. The use of the term inflammatory lateral periodontal cyst, previously suggested by Main (1985)<sup>5</sup> should be avoided to prevent confusion with the developmental lateral periodontal cyst. The other term used to describe this entity was 'Mandibular infected buccal cyst'.<sup>6</sup>

It seems clear that the paradental cyst is of inflammatory origin and that it arises from odontogenic epithelium. The histogenesis of this cyst has been widely discussed and three possible origins are generally accepted: crevicular epithelium, the cell rests of Malassez and the reduced enamel epithelium. Craig (1976)<sup>3</sup> has suggested that either the cell rests of Malassez or the reduced enamel epithelium might provide the cell of origin. He favored the latter source because in his study, the rest of Malassez always appeared inactive and that if the Malassez rests were responsible, the lesion should be equally distributed around the root surface. His serial sections indicated that the development of paradental cyst may follow hyperplasia and cystic change in reduced enamel epithelium. He suggested that the presence of an extension of reduced enamel epithelium over the enamel projections might be the source and could explain the frequent buccal location of the cyst.

## PATHOGENESIS

There is no unanimity with regard to pathogenesis of the cyst. Ackermann et al (1987)<sup>7</sup> like Craig<sup>3</sup> favored origin from reduced enamel epithelium but suggested that cyst formation occurs as a result of unilateral expansion of the dental follicle secondary to inflammatory destruction of periodontium and the alveolar bone. Fowler and Brannon<sup>8</sup> suggested that it may be a variant of the dentigerous cyst or derived from an occluded periodontal pocket. Vedtofte and Praetorius (1989)<sup>4</sup> were satisfied that the cyst was of inflammatory origin initiated by a pericoronitis at the time of tooth eruption and considered rest of Malassez and reduced enamel epithelium the most likely sources of the cyst epithelium.

<sup>1,4</sup>Professor, <sup>2</sup>Lecturer, <sup>3</sup>Associate Professor and Vice Dean

<sup>1</sup>Department of Oral Pathology, College of Dentistry, King Saud Bin Abdulaziz University for Health Sciences, National Guard Health Affairs, Riyadh, Saudi Arabia

<sup>2</sup>Department of Oral Microbiology, College of Dentistry, King Saud Bin Abdulaziz University for Health Sciences, National Guard Health Affairs, Riyadh, Saudi Arabia

<sup>3</sup>Department of Endodontics, College of Dentistry, King Saud Bin Abdulaziz University for Health Sciences, National Guard Health Affairs, Riyadh, Saudi Arabia

<sup>4</sup>Department of Periodontics, College of Dentistry, King Saud University, Riyadh, Saudi Arabia

**Corresponding Author:** Hari Pillai, Lecturer, Department of Oral Microbiology, College of Dentistry, King Saud Bin Abdulaziz University for Health Sciences, National Guard Health Affairs, Riyadh, Saudi Arabia, Phone: 00966536355831 e-mail: pathman022002@yahoo.co.in

## CLINICAL FEATURES

### Frequency

The paradental cyst is considered as a rare lesion and was included in the World Health Organization (WHO) histological typing of odontogenic tumors for the first time in 1992. The relatively recent characterization of this cyst can be a contributing factor to its nonrecognition and has been speculated that this lesion was underdiagnosed.<sup>9</sup> Lindh and Larsson<sup>10</sup> believed that the paradental cyst has been misdiagnosed as a dentigerous cyst, lateral periodontal cyst or merely as pericoronitis or some other entity related to inflammatory conditions of the dental follicle. Another fact that could result in the underdiagnosis of paradental cyst is that histopathological confirmation of extirpated follicular sacs is rarely done.

The prevalence of paradental cyst is low compared to other cysts, representing 3 to 5% of all odontogenic cysts.<sup>7,11</sup> In the mandible, this lesion was detected in only 26 (0.9%) of the 2700 cyst cases studied by Magnusson and Borrmann.<sup>12</sup> In regard to the lower third molars, this can be considered the second most frequent cyst, representing up to 25% of the cystic lesions, although they represented only 1.6% of the cystic lesions reported by Colgan et al.<sup>13</sup>

The paradental cyst is localized exclusively in the mandibular region, almost always on the distal or buccal side of a completely or partially erupted molar which are vital in nature. Although the mesial surface could also be involved very rarely, the lingual aspect is almost always spared. More than 60% of the cases of paradental cysts are associated with the lower third molar.<sup>14</sup> No particular predilection was reported for the right or left side. A reported history of one or more episodes of pericoronitis was reported in most cases.

### Age and Sex

The median age of the patients with paradental cysts localized at the lower first molar was 8 to 9 years, whereas cysts localized to the second molar appeared between 13 and 20 years of age (total of 342 cases) with a male:female ratio of 2.4:1.<sup>14</sup> Philipsen et al<sup>19</sup> demonstrated that only 61.4% of paradental cysts occurred in the mandibular third molar region. This is in contrast to the data published by Jones et al<sup>15</sup> who reported a figure of 99.4%. Bilateral localizations were marked in 23.6% of cases. A total of 402 paradental cysts were identified<sup>15</sup> with a mean age group of 29 years and a male:female ratio of 1.37:1. In the respective age groups, paradental cysts were twice more common in adults than in children (5.9 and 2.7% respectively). Among the 54 cysts that satisfied the criteria for classification as paradental cysts,<sup>11</sup> 33 cysts occurred

in female patients ranged from 13 to 47 years, but most of the patients were between 20 and 30 years of age.

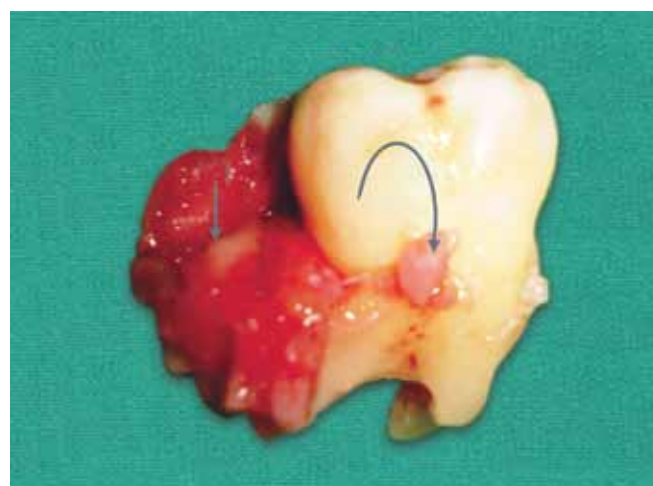
### Race

No racial predilection reported.

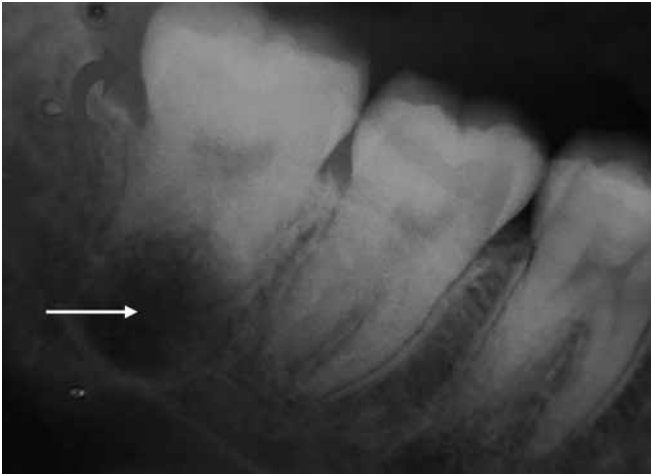## CLINICAL PRESENTATION

A positive electric pulp test of the associated tooth is a good diagnostic criterion for paradental cyst, associated with other clinical characteristics. If the tooth is nonvital, the possibility is more for a lateral radicular (infective) cyst. However, undue reference need not be given to this single character of the cystic lesion.

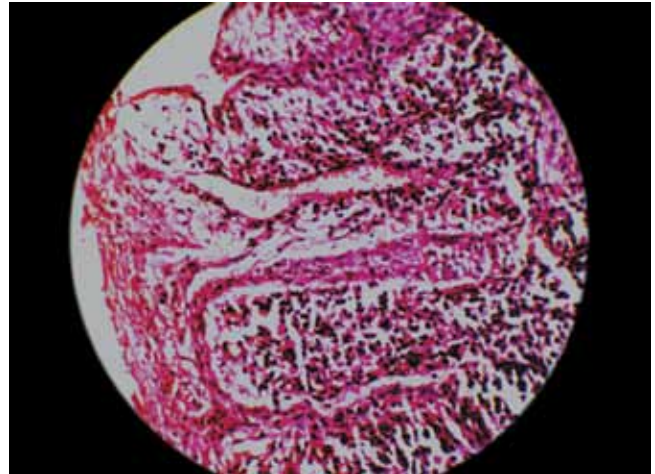
The major clinical feature of the paradental cyst is the presence of a recurring inflammatory process usually presenting as pericoronitis (Fig. 1). The cyst usually presents with mild signs and symptoms including local discomfort, tenderness, painful swelling and in some cases suppuration through the periodontal pocket. The clinical signs and symptoms are those of periodontitis and are common irrespective of the tooth affected. The onset of a vestibular swelling seems to be associated exclusively to the paradental cyst. Since the lesion is localized to the vestibular aspect of the roots, the involved molar is usually tilted, so that the root apices are adjacent to the lingual cortex with the crown showing buccal tipping. In the case of paradental cysts, there is often the presence of a communication between the periodontal pocket and the cystic lumen, but the cortical expansion of the bone is not so frequent like other cysts arising from odontogenic epithelium. The majority of lesions do not exceed 15 mm of diameter.<sup>16</sup>



**Fig. 1:** The extracted tooth specimen with a large hyperplastic dental follicle on the distal aspect (straight arrow) and a fragment of the cystic lesion attached on the buccal surface at the cemento-enamel junction (curved arrow) (Courtesy: Diagnostic features of the paradental cyst and report of a case. *Dentomaxillofacial Radiology* 2009;38:125-126)



**Fig. 2:** Periapical radiograph showing a sharply delineated radiolucent lesion epicentered around the furcation area in relation to the left mandibular third molar (straight arrow); preservation of the follicular space is also appreciated (curved arrow) (Courtesy: Diagnostic features of the paradental cyst and report of a case. Dentomaxillofacial Radiology 2009;38:125-126)



**Fig. 3:** Photomicrograph showing cystic lining with dense inflammatory infiltrate (hematoxylin and eosin staining: 20x magnification) (Courtesy: Diagnostic features of the paradental cyst and report of a case. Dentomaxillofacial Radiology 2009;38:125-126)

**RADIOLOGICAL FEATURES**

Radiographically, they usually present as well-defined radiolucencies superimposed on the roots of the affected tooth, located either mesially or distally to a partially erupted mandibular molar (usually third). The roots of the tooth can be displaced with variable expansion of the buccal plate (Fig. 2). Bohay et al<sup>17</sup> demonstrated thinning of the inferior border of the mandibular cortex, without expansion. The patients usually experience delayed eruption of the associated tooth with repeated episodes of pericoronitis. There are some features that appear consistently and which seem to be useful in contributing to the diagnosis. These are the nonwidening of the periodontal ligament space, and when there was a distal as well as a buccal radiolucency, the distal element was separate from the buccal with a distinct distal follicular space.<sup>18</sup> The presence of the ‘Colgan’s sign’, which is the preservation of the distal follicular space in the radiograph is a useful diagnostic feature to distinguish paradental cyst from dentigerous cyst.<sup>13</sup>

**HISTOPATHOLOGICAL FEATURES**

The histopathological features of the paradental cyst are identical to the radicular cysts and to those of other odontogenic cysts. Microscopic examination shows a fibrous connective tissue capsule invaded by chronic inflammatory infiltrate, associated with hyperplastic, nonkeratinized, stratified squamous epithelium showing arcade formation (Fig. 3).

**TREATMENT**

Most reports show that, if the tooth involved is the first or the second molar, the treatment of choice is enucleation

of the cyst without extracting the associated tooth; however, extraction of the tooth and the paradental cyst has been considered the treatment of choice when the involved tooth is a third molar.<sup>14</sup> Pompura et al<sup>20</sup> presented 44 cases treated by enucleation without extraction. In all cases, recurrence was rare provided that the lesion has been completely removed.

**REFERENCES**

1. Main DM. Epithelial jaw cysts: a clinicopathological reappraisal. Br J Oral Surg 1970 Nov;8(2):114-125.
2. Chrcanovic BR, Reis BM, Freire-Maia B. Paradental (mandibular inflammatory buccal) cyst. Head and Neck Pathology 2011 Jun;5(2):159-164.
3. Craig GT. The paradental cyst: a specific inflammatory odontogenic cyst. Br Dent J 1976 Jul;141(1):9-14.
4. Vedtofte P, Praetorius F. The inflammatory paradental cyst. Oral Surg Oral Med Oral Pathol 1989 Aug;68(2):182-188.
5. Main DM. Epithelial jaw cysts: 10 years of the WHO classification. J Oral Pathol 1985 Jan;14(1):1-7.
6. Shear M. Cysts of the jaws: recent advances. J Oral Pathol 1985 Jan;14(1):43-59.
7. Ackermann G, Cohen MA, Altini M. The paradental cyst: a clinicopathologic study of 50 cases. Oral Surg Oral Med Oral Pathol 1987 Sep;64(3):308-312.
8. Fowler CB, Brannon RB. The paradental cyst: a clinicopathologic study of six new cases and review of the literature. J Oral Maxillofac Surg 1989 Mar;47(3):243-248.
9. Borgonovo AE, Reo P, Grossi GB, Maiorana C. Paradental cyst of the first molar: report of a rare case with bilateral presentation and review of the literature. J Ind Soc Pedod Preven Dent 2012 Oct-Dec;30(4):343-348.
10. Lindh C, Larsson A. Unusual jaw-bone cysts. J Oral Maxillofac Surg 1990 Mar;48(3):258-263.
11. De Sousa SO, Correa L, Deboni MC, de Araujo VC. Clinicopathologic features of 54 cases of paradental cyst. Quintessence Int 2001 Oct;32(9):737-741.

12. Magnusson B, Borrman H. The paradental cyst a clinico-pathologic study of 26 cases. *Swed Dent J* 1995;19(1):1-7.
13. Colgan CM, Henry J, Napier SS, Cowan CG. Paradental cysts: a role for food impaction in the pathogenesis. A review of cases from Northern Ireland. *Br J Oral Maxillofac Surg* 2002 Apr;40(2):163-168.
14. Reichart P, Philipsen HP. The development and fate of epithelial residues after completion of the human odontogenesis with special reference to the origins of epithelial odontogenic neoplasms, hamartomas and cysts. *Oral Biosci Med* 2004;1(3): 171-179.
15. Jones AV, Craig GT, Franklin CD. Range and demographics of odontogenic cysts diagnosed in a UK population over a 30-year period. *J Oral Pathol Med* 2006 Sep;35(8): 500-507.
16. Shear M, Speight P. Cysts of the oral and maxillofacial regions. 4th ed. Wiley-Blackwell Publishers 2007. p. 143-149.
17. Bohay RN, Weinberg S, Thorner PS. The paradental cyst of the mandibular permanent first molar: report of a bilateral case. *ASDC J Dent Child* 1992 Sep-Oct;59(5):361-365.
18. Shear M, Seward GR. Cysts of the oral regions. 4th ed. Blackwell Munksgaard; 2007. p. 144-146.
19. Philipsen HP, Reichart PA, Ogawa I, Suei Y, Takata T. The inflammatory paradental cyst: a critical review of 342 cases from a literature survey, including 17 new cases from the author's files. *J Oral Pathol Med* 2004 Mar;33(3):147-155.
20. Pompura JR, Sandor GK, Stoneman DW. The buccal bifurcation cyst: a prospective study of treatment outcomes in 44 sites. *Oral Surg Oral Med Oral Pathol Oral Radiol Endod* 1997 Feb;83(2):215-221.

